



## A comparative review of various interventional methods for coronary angiography and angioplasty

Asieh Dehghani<sup>1</sup>, Farshad Roghani-Dehkordi<sup>2\*</sup>

1. Faculty of Nursing and Midwifery, Young Researchers and Elite Club, Isfahan (Khorasgan) Branch, Islamic Azad University, Isfahan, Iran.
2. Department of Cardiology, School of Medicine, Isfahan University of Medical Sciences, Isfahan, Iran.

### Abstract

**Background and Objective:** Coronary artery disease (CAD) is one of the most common diseases today. Among the diagnostic methods, angiography is the main and gold standard in the diagnosis. Since angiography is an invasive procedure, this procedure complications range widely from minor problems with short term sequelae to life threatening ones may cause irreversible damage or even death.

**Materials and Methods:** This paper is a review study and papers published within the period of 2002-2017 were assessed. To obtain related scientific documents, web surfing was conducted in Persian and English using various keywords including angiography, coronary artery disease, angiography complications, patient satisfaction, femoral angiography, radial angiography, ulnar angiography, superficial palmar branch of ulnar artery, and snuff box angiography. Papers related to this subject were extracted from the Web of Science (ISI), PubMed, Magiran, Google Scholar, Elsevier, Ovid, and SID databases.

**Results:** Out of the 100 retrieved studies, 31 (3 cross sectional, 1 analytical descriptive, 7 descriptive studies, 6 reviews, 2 RCT, 5 Cohorts, 1 Case Report, and 6 Case series) were entered into this study. In addition, 69 records were excluded for wrong statistics reported, duplicate studies, lack of enough information, and lack of relevance to this study.

**Conclusion:** According to most studies, the procedure via hand for angiography is better than the lower extremity (femoral). In addition, it seems that the use of distal upper extremities for angiography is better than the radial and ulnar method. However, more research evidence is strongly warranted.

**Keywords:** Coronary angiography, Coronary angioplasty, Coronary artery disease

### 1. Introduction

The aorta is the main blood supplier to the body. The aorta branches off into two main coronary blood vessels; i.e. the right and left coronary arteries.

These coronary arteries branch off into smaller arteries, which supply oxygen-rich blood to the entire heart muscle. Various factors affect the normal operation of these vessels and they are related to coronary artery disease (CAD). The most important risk factors are high cholesterol, smoking, hypertension, diabetes mellitus, obesity and inactivity (1,2). CAD is one of the most common diseases today that leads to the highest mortality rates in the developed and developing countries (1). According to

reports of centers for Disease Control and Prevention (CDC); each year 1.5 million people are suffering from cardiovascular disease that 15 to 65 percent of these numbers are associated with death (3). According to the forecast of the World Health Organization (WHO) in the following years, not only the prevalence of the disease will not reduce, but in 2020, the mortality rate of the disease will reach to 25 million per year. In Iran due to changes in the structure of society and industrialization and population density, coronary artery diseases are the most common non-communicable diseases and the most important cause of death; so that more than 39.3% of deaths in Iran is related to ischemic heart

diseases (3). Heart disease causes many of economic and casualties losses; So, that health authorities in different countries are forced to make strategic planning for education, prevention and treatment in this field (3). Early diagnosis and treatment of coronary artery diseases can reduce mortality and morbidity in patients. Among the diagnostic methods, angiography is the main and gold standard in the diagnosis (1,2). During catheterization, small tubes (catheters) are inserted into the circulatory system under x-ray guidance in order to obtain information about blood flow and pressures within the heart and to determine if there is any obstruction within the blood vessels feeding the heart muscle (coronary arteries). It should be noted that obstruction of the arteries is caused by plaque build-up, and when severe they can cause a variety of symptoms including chest pain and shortness of breath (4). Also, angiography provides the most reliable information for assessment of medical therapy as well as interventional procedures such as percutaneous coronary intervention (PCI) or coronary artery bypass graft (CABG) in patients with CAD (4,5).

Since angiography is an invasive procedure, this procedure complications range widely from minor problems with short term sequelae to life threatening ones may cause irreversible damage or even death. Its complications are: allergic local and systemic reactions, thromboembolic complications, infections, nephropathy, cholesterol emboli, local vascular injury, hematoma and retroperitoneal haemorrhage, arteriovenous fistula, bradyarrhythmia, tachyarrhythmia, death, myocardial infarction, cerebrovascular complications such as stroke, dissection and perforation of great vessels, hypotension, hypoglycemia, respiratory insufficiency (6). The most common complication associated with coronary angiography is bleeding at the access site. Fortunately, the associated risks have significantly decreased since the invention of coronary arteriography due to advanced equipment design, improved peri-procedural management, increased experience of diagnostic centers and operators, use of iso-osmolar contrast media, lower profile diagnostic catheters, and measures to reduce the incidence of bleeding. Major complications from cardiac catheterization are uncommon, they occur in less than 2% of the population, with mortality rate less than 0.08% (6,7).

With regard to the importance of angiography in the diagnosis and treatment of patients as well as an increase in the rate of performing angiography, this study was conducted to evaluate and compare angiography methods via femoral, radial, ulnar, superficial palmar branch of ulnar artery, and snuff box.

## 2. Materials and Methods

This is a review study and papers (research documents) published within the period of 2002-2017 were investigated. To obtain related scientific documents, web surfing was conducted in Persian and English using various keywords including angiography, coronary artery disease, angiography complications, patient satisfaction, femoral angiography, radial angiography, ulnar angiography, superficial palmar branch of ulnar artery, and snuff box angiography. Conducting this search, papers related to this subject were extracted from the Web of Science (ISI), PubMed, Magiran, Google Scholar, Elsevier, Ovid, and SID databases. Out of the 100 retrieved studies, 31 (3 cross sectional, 1 analytical descriptive, 7 descriptive studies, 6 reviews, 2 RCT, 5 Cohorts, 1 case report, and 6 case series) were entered into this study. In addition, 69 records were excluded for wrong statistics reported, duplicate studies, lack of enough information, and lack of relevance to this study.

## 3. Results and discussion

Coronary angiography is performed through percutaneous approach for arteries; therefore, selecting the best vascular access is one of the first decisions for any percutaneous cardiovascular procedure. In 1950, Zimmerman reported on retrograde left heart catheterization using the left ulnar artery. In 1959, Sones performed selective coronary angiography via the much larger brachial artery, using a surgical cut-down. Thereafter, cardiovascular interventionists began to use femoral access for PCI due to some complications of brachial access in 1967. However, this new access site has shown to have several complications as well. The background of radial artery access for angiography dates back to March 1947 with Radner in Lund, Sweden. In 1964, Campeau and Bourassa had begun to use the proximal radial artery instead of the brachial. Kiemeneij open a new window in coronary interventional cardiology in the early 1990s by performing balloon angioplasty as well as stent implantation through the radial artery. After that, Trashima and his colleagues were the first who reported the feasibility of trans-ulnar approach for diagnostic catheterization of coronary arteries more than one decade ago. Ulnar artery has been shown to result in significantly less clinical complications (5). Then the snuff box and the Superficial palmar branch of the ulnar artery have been used recently. In the following, each of these methods will be explained.

### 3.1. Femoral angiography

Femoral artery is the most used access for angiography. It is used for diagnostic and interventional coronary angiography (8). It has a longer history of use and have been shown to be more technically straightforward to perform compared with procedures conducted through the radial artery. The femoral approach also allows for the use of larger diameter catheters and sheaths, when necessary. Compared to the radial approach, coronary angiography procedures via the femoral artery consistently demonstrate reduced volume of contrast, shorter procedural times, and less x-ray exposure (9). But, it is relatively contraindicated in the presence of severe peripheral vascular disease and in patients receiving anticoagulation treatment (10). Also, this approach has disadvantages. Trans-femoral artery approach may result in major life or limb-threatening complications, and remains the leading cause of morbidity after cardiac catheterization (11). Local complications of the femoral angiography can vary from painful hematomas (resolved spontaneously) to the retroperitoneal hemorrhage which is a life-threatening complication. If the artery access compared to the inguinal crease be very proximal, it leads to the retroperitoneal bleeding, but if the arterial access be very distal, it leads to hematoma, pseudoaneurysm, and arteriovenous fistula. The most common vascular complication in the femoral angiography is hematoma in the groin site (8). Predictors of vascular complications are female gender, history of HTN, shorter height, and higher BMI. Female gender, emergency surgery, sheet size, and renal failure and anti-coagulants (8). After arterial sheath removal, the patient will need to lie flat without bending the leg for 2 to 6 hours to allow the artery to complete hemostasis (4). A period of post-procedure recumbency is needed. This may be poorly tolerated by patients with left ventricular dysfunction, lung disease, or back and hip pain (10). In some cases, even with prolonged immobility, internal bleeding can occur and can be severe enough to require blood transfusions or surgery to repair the femoral artery. These complications are rare, but they may be less common if the catheter is inserted in the wrist (4). It has even been stated that the coronary angiography via the femoral artery access should be considered in the case of severe hand ischemia (5).

### 3.2. Radial angiography

The hand receives dual blood supply through the ulnar and radial arteries via the palmar arch (6,12). Therefore, any radial artery occlusion (reported in 5-19% of cases) (13) is not clinically important in most patients because the hand is perfused by extensive collateral flow paths between the two arteries. Most operators prefer the right radial approach. The main reason is the working position of the operator on the

right side of the patient. Frequently the operator needs to crossover to the left radial approach. Most common reasons to use the left radial artery instead of the right radial one are: right radial occlusion, under-developed right radial artery, extreme right radial tortuosity, sclerosis or calcifications, arteria lusoria, previous right radial failure, presence of an arteriovenous-shunt in the right arm, past or future use of right radial artery as free arterial graft, post CABG patients requiring LIMA angiography, and patient preference. In terms of feasibility and outcome, left and right trans-radial approaches are similar (14).

Trans-radial artery approach for coronary intervention has gained solid recognition as an alternative to the standard trans-femoral artery approach (11,15,16). Also, transradial approach is safer than transfemoral because the rate of local and major vascular complications was negligible using the transradial approach when compared with transfemoral route (11, 16-18). The radial artery is not contiguous with nearby nerves or veins, allowing for improved hemostasis (6). Because the radial artery is much smaller and located closer to the skin surface, internal bleeding is eliminated and any external bleeding can be easily compressed (4). In addition, transradial artery approach is associated with shorter hospital stay, greater satisfaction and comfort to the patients, and lower cost (4,11,12, 15). In many studies, it has been stated that both women and men would prefer radial access and they feel satisfaction (6,18). Patients can mobilize as soon as the arterial sheath is removed on completion of the procedure (12). Schwalm in 2012 cites from Bertrand et al. that vascular access through the radial artery requires the patient to lie flat for a significantly shorter period of time and has a shorter bed rest period following the procedure and there is no need for heavy pressure on the leg, when compared with the femoral approach. This has significant implications for patients with chronic back pain (4,7).

However, access to the radial artery is not always successful. Failure to get radial access is mainly attributed to difficulty in puncturing the artery due to arterial spasm and infrequently to presence of a radial loop-hypoplasia, or occlusion of the radial artery (11). Spasm of the muscles lining the wall of the radial artery is temporary, and can be prevented and treated with medications in the majority of cases. Occasionally, it can be severe enough to necessitate cross over to another arterial access. Also, the radial artery may occlude after the procedure. This may result because of a blood clot forming in the artery. Anticoagulants given during the procedure help to prevent this, and with modern techniques it has become rare. Its incidence is less than 2% of cases (4). In addition, in radial approach the contrast agent used more than the femoral approach (9). Also, Procedural duration and radiation exposure are higher using the transradial access (12, 17). It should be noted that

experiences of the surgeon has important role in the success and during the procedure (12). In 2015, a study conducted by Pandie et al. indicated that women are at greater risk of post-PCI bleeding and that radial access may reduce this risk, but operators may be reluctant to use radial access in women because of increased radial artery spasm, smaller arteries, and greater tortuosity (18).

The most important factor driving the decision to use the radial artery or the femoral artery is the physician performing the procedure. There are also many physicians who use the radial approach in selective situations where the femoral approach may be more complicated, such as in obese patients or patients with obstructions in the blood vessels supplying the lower extremity. The femoral approach may be selected for patients in whom preservation of the radial artery is essential, such as patients requiring dialysis fistulas or patients who require the radial artery to be used for bypass surgery (4).

### 3.3. Ulnar artery

The ulnar artery is rarely selected for coronary procedures (19). It has become the alternative approach when the radial artery cannot be accessed or used (11). Potential advantages of the trans-ulnar access include of serve as an alternative access artery for repeated angiographies; thereby minimizing the trans-femoral approach (19). In some studies, it has been stated that ulnar approach could be consider as a safe and practical method with only minor and easily resolvable complications (5, 11, 20). Salim's study in 2010 cited by Kiemeneij et al. stated that the technical success rate is 95-96% through trans-ulnar route (20). Ulnar artery is usually larger than radial which may make it less disposed to catheter-induced vasospasm compared to the radial artery and it leads to more satisfied patients. Furthermore, this can lead to taking advantage of larger arterial sheaths (5, 21, 22). An additional advantage in using the trans-ulnar approach is that it can preserve the future use of the radial artery as a conduit for coronary artery bypass surgery (20). Also, this approach has disadvantages. It has minor and major complications. Major complications of the ulnar approach such as pulselessness, ulnar nerve damage, compartment syndrome, need to blood transfusion or hand amputation, myocardial infarction or pseudoaneurysm, AV fistula and ulnar artery occlusion. Minor complications of the ulnar approach such as low grade hematoma (Grade 1 hematoma: under 5 cm subcutaneous hematoma or Grade 2: under 10 cm), pain, irritation of ulnar nerve, and methods for resolving the complications and patients outcomes (5). Complications such as local hematoma, ulnar artery perforation and reversible parasthesia can occur in 1% of patients (20). Risk factors of complications in the ulnar approach were emergent procedure, severe tortuosity of ulnar artery, narrowing of ulnar artery

(5). In a study conducted by Sallam et al. in 2014, it was stated that the ulnar artery has a less intense pulse when compared to the radial artery. One third of patients had impalpable or weak ulnar pulse, which is attributed to deep location of the ulnar artery beneath the muscle (11). It was recommended to perform Doppler sonography of upper limb in patients with persistent signs or weak pulses (5). Moreover, the ulnar nerve runs close to the artery and patients may experience neurological discomfort during the puncture (11). It is believed that applying a proper size needle and careful placement of it would be helpful to avoid the occurrence of this complication (5).

### 3.4. The Superficial palmar branch of the ulnar artery and the snuffbox

The anatomical snuffbox is a depression in wrist's radial part, limited by the tendons of abductor pollicis longus muscle, extensor pollicis brevis and extensor pollicis longus muscles (23). It is deep palmar branch of radial artery in dorsum of hand (24). Sometimes, the operator needs to crossover to the left radial approach. However, the left radial access is cumbersome for the operator, especially in obese patients. The arm in volar position limits flexion of the forearm towards the operator. The operator therefore needs to bend over the patient, which is ergonomically very unpleasant. In addition, the operator is exposed to higher radiation doses because of closer proximity to the radiation source and due to radiation scatter from the patients' body (25). The study of Kiemeneij demonstrates the feasibility of left radial approach via the distal radial artery located at the anatomical snuffbox. In this method, there is no puncture trauma, no vessel wall damage by sheath introduction and no trauma by prolonged hemostatic occlusion. Since antegrade flow through the superficial palmar arch is still maintained, the radial artery will not thrombose in case of occlusion of the radial artery in the snuffbox. This is relevant for patients requiring multiple radial artery procedures or requiring coronary bypass surgery with use of a free radial artery graft. Another advantage is the short (2-3 hours) hemostasis time, because of the superficial position of this small vessel. Kiemeneij believed that this new approach is as a further refinement in trans-radial interventions (25). Dr. Babunashvili is pioneer of distal radial artery access and who performed over 700 procedures, ultrasound guided puncture is recommendable for proper patient selection and safer and more successful puncture (26).

Risks and possible consequences in use of snuffbox are injury to the superficial branch of the radial nerve, arteriovenous fistulas failures and radial artery aneurysms due to multiple attempts of puncture (23). The distal radial artery is small, making puncture more challenging. A learning curve has to be overcome. In this small series of patients, this artery

was too weak to attempt a puncture at the radial fossa in 23% of cases (25).

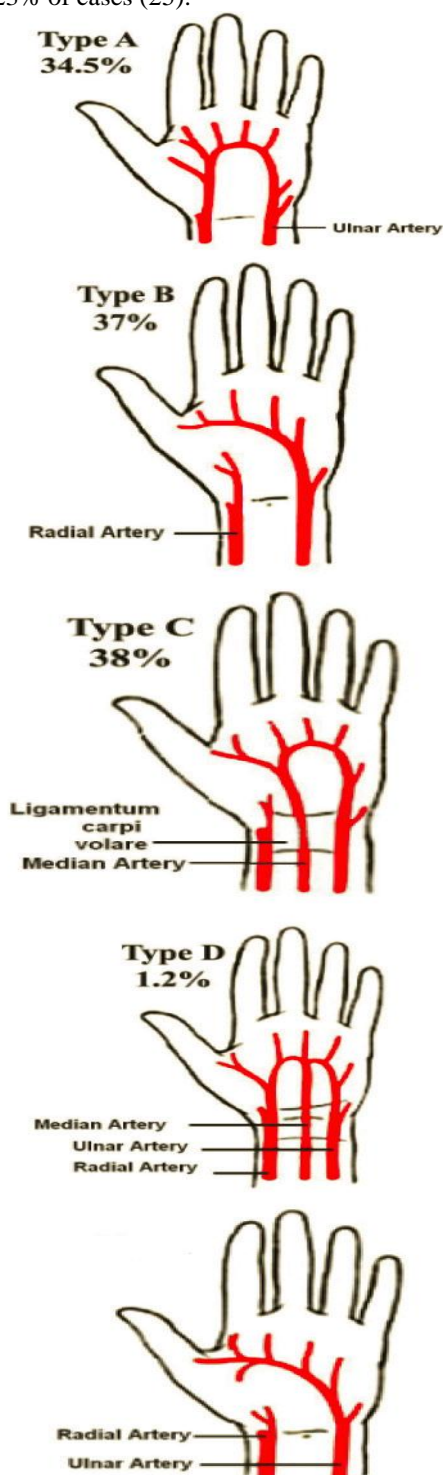


Figure 1: Classification of the superficial palmar arch

In a study, Roghani et al presented a new innovative approach using more distal route, i.e. palmar artery (superficial palmar branch of ulnar artery) and snuff box artery. This new approach may be suggested as a safe and reliable approach with lower complications to be used for coronary angiography and/or intervention (25). According to their observations, distal accesses

in smaller arterial branches have been associated with lower risk of bleeding with easier practice of hemostasis and discharge. In case of distal arterial occlusion following angiography or angioplasty procedure, thrombotic burden is limited to distal vessels and forearm arteries are still preserved for future use. In addition, distal access can be used for recanalization of occluded radial and/or ulnar arteries. In a study conducted by Roghani et al. in 2017, it was stated that the sheath removed immediately post PCI (24). In addition, this technique can be considered for cases with radial spasm at the wrist level (25). Many patients leaved the ward in an ambulatory fashion and at the same day discharged. No vascular complications occurred despite intense anticoagulation. Hemostasis was very fast (10- 15 min) without any compression device (Roghani et al., 2017). No ischemic complications by this technique is expected, because the puncture point is located between the ramus palmaris superficialis and the ostium of the princeps pollicis artery (24, 25, 27).

### 3.5. The Superficial palmar branch of the ulnar artery

Hand has derived its arterial supply from two anastomotic arches, superficial and deep palmar arches which are formed between two main arteries of forearm i.e. radial, ulnar and their branches, in the palm (28). Superficial Palmar Arch (SPA) is an arterial arcade and a dominant vascular structure in the palm. It is defined as the anastomosis between the superficial branch of the ulnar artery and superficial palmar branch of the radial artery (29). The superficial palmar branch of the radial artery entered the hand through the thenar muscles and provided palmar digital branches to the radial side of the index finger and the ulnar side of the thumb, without any contribution to the SPA. However, the radial side of the thumb was supplied by a branch from the deep palmar arch. The superficial branch of the ulnar artery gave origin to three common palmar digital arteries to supply the contiguous sides of the index, middle, ring and little fingers. It also provided origin to a digital branch to the ulnar side of the little finger (30). SPA is an anastomosis, fed mainly by the ulnar artery. When the ulnar artery is occluded, the viability of the structures in the palm supplied by the ulnar artery depends on the efficacy of the collateral circulation. If there will be no collateral flow of blood to meet the metabolic demands of the palmar tissue, this will result in acute ischaemia, manifested by claudications, rest pain and/or gangrene (30).

Coleman and Anson in 1961 (Figure 1), classified the superficial palmar arch in two groups, Group I and Group II as follows:

**Group I:** Complete Arch: Contributing vessels anastomose with each other which are further divided into five types.

**Group II:** Incomplete Arch: Contributing vessels do not anastomose with each other which are further divided into four types that is, A, B, C, D similar to Group I (except Type E which has no representation in Group II) (28).

Type A: Classical radio ulnar arch: Formed by superficial palmar branch of radial artery and the larger ulnar artery (34.5%).

Type B: Arch formed entirely by ulnar artery (37%).

Type C: Mediano – Ulnar arch: Composed of ulnar artery and an enlarged median artery (38%).

Type D: Radio – mediano-ulnar arch: Three vessels enter into formation of the arch (1.2%).

Type E: Arch initiated by ulnar artery and completed by a large sized vessel derived from deep arch (28).

## Conclusion

Each of the angiographic methods has advantages and disadvantages, but according to most studies, it has been proven that the procedure via hand for angiography is better than the lower extremity (femoral). In addition, it seems that the use of distal upper extremities for angiography is better than the radial and ulnar methods, although more researches are needed in this field. Also, the doctor's decision and skill is important to choose the method. The number of procedures attempted will increase with improved operator experience.

## Conflict of interest

There is no conflict of interest to report.

## References

- Dianati M, Mousavi MS, Feshangchi S, RezaieShahvarloo Z, Lotfi MS, Vaghefi M. The study of coronary angiography results in patients referred to coronary angiography laboratory of Shahid Beheshti Hospital from November 2010 to April 2011. *Iranian Journal of Cardiovascular Nursing* 2013; 2(1): 48- 54.
- Abdollahimoghadam A, Raffieijelodar H, Ebrahimi M. Prevalence of renal artery stenosis and its risk factors in female patients undergoing coronary angiography. *The Iranian Journal of Obstetrics, Gynecology and Infertility* 2013; 16(51): 7- 13.
- Bijani M, Valizadeh A, Sayari A, Samizadeh B. Surveying the reasons for refusing coronary angiography in patients referring to cardiac ward of Valiasr hospital in Fasa. *Journal of Fasa University of Medical Sciences* 2015; 4(4): 375- 381.
- Balaji NR, Shah PB. Radial artery catheterization. *Circulation* 2011; 24: e407-e408.
- Roghani-Dehkordi F, Hadizadeh M, Hadizadeh F. Percutaneous trans-ulnar artery approach for coronary angiography and angioplasty; A case series study. *ARYA Atherosclerosis* 2015; 11(5): 305-309.
- Tavakol M, Ashraf S, Brener SJ. Risks and complications of coronary angiography: a comprehensive review. *Global Journal of Health Science* 2012; 4(1): 65-93.
- Roghani-Dehkordi F, Mansouri R, Khosravi A, Mahaki B, Akbarzadeh M, Kermani-Alghoraishi M. Transulnar versus transradial approach for coronary angiography and angioplasty: Considering their complications. *ARYA Atherosclerosis* 2018;14(3):128-131.
- Yousefi AA, Madani M, Azimi HR, Farshidi H. The factors relevant to the onset of vascular complications after coronary intervention in Shahid Rajaei Cardiovascular Center in Tehran, Iran. *Tehran University Medical Journal* 2011; 69(7): 445- 450.
- Schwalm JD, Stacey D, Pericak D, Natarajan MK. Radial artery versus femoral artery access options in coronary angiogram procedures. *Circulation Cardiovascular Quality and Outcomes* 2012; 5: 260-266.
- Archbold RA, Robinson NM, Schilling RJ. Radial artery access for coronary angiography and percutaneous coronary intervention. *British Medical Journal* 2004; 329(7463): 443-446.
- Sallam M, Al-Riyami A, Misbah M, Al-Sukaiti R, Al-Alawi A, Al-Wahaibi A. Procedural and clinical utility of transulnar approach for coronary procedures following failure of radial route: Single centre experience. *Journal of the Saudi Heart Association* 2014; 26:138-144.
- Tayeh O, Etori F. Coronary angiography safety between radial and femoral access. *The Egyptian Heart Journal* 2014; 66, 149-154.
- Roghani-Dehkordi F, Hashemifard O, Sadeghi M, Mansouri R, Akbarzadeh M, Dehghani A, et al. Distal accesses in the hand (two novel techniques) for percutaneous

- coronary angiography and intervention. *ARYA Atherosclerosis* 2018;14(2):95-100.
14. Shah RM, Patel D, Abbate A, Cowley MJ, Jovin IS. Comparison of transradial coronary procedures via right radial versus left radial artery approach: A meta-analysis. *Catheterization and Cardiovascular Interventions* 2016; 88(7):1027-1033.
  15. Tarighatnia A, Mohammad Alian AH, Ghojzadeh M, Farajollahi AR. Comparison of the patient radiation exposure during coronary angiography and angioplasty procedures using trans-radial and trans-femoral access. *Journal of Cardiovascular and Thoracic Research* 2016; 8(2), 77-82.
  16. Bhat FA, Changal KH, Raina H, Trambo NA, Rather HA. Transradial versus transfemoral approach for coronary angiography and angioplasty– A prospective, randomized comparison. *BMC Cardiovascular Disorders* 2017; 17:23- 29.
  17. Brueck M, Bandorski D, Kramer W, Wieczorek M, Höltingen R, Tillmanns H. A Randomized comparison of transradial versus transfemoral approach for coronary angiography and angioplasty. *Journal of the American College of Cardiology* 2009; 2(11): 1047-1054.
  18. Pandie S, Mehta SR, Cantor WJ, Cheema AN, Gao P, Madan M, et al. Radial versus femoral access for coronary angiography/intervention in women with acute coronary syndromes. *Journal of the American College of Cardiology* 2015; 8(4): 505-512.
  19. Hahalis G, Tsigkas G, Xanthopoulou I, Deftereos S, Ziakas A, Raisakis K, et al. Transulnar compared with transradial artery approach as a default strategy for coronary procedures: a randomized trial. *Circulation Cardiovascular Interventions* 2013; 6: 252-261.
  20. Salim A, Ahsan SA, Siddique A, Banerjee SK, Rahman AF, Ahmed C, et al. Initial experience of coronary angiogram through trans ulnar route in Bangabandhu Sheikh Mujib Medical University. *University Heart Journal* 2013; 9(2): 80-82.
  21. Khosravi A, Pourbehi MR, Pourmoghaddas M, Akhbari MR, Ziaee-Bideh F. Evaluating the impact of fractional flow reserve-guided percutaneous coronary intervention in intermediate coronary artery lesions on the mode of treatment and their outcomes: An Iranian experience. *ARYA Atherosclerosis* 2015; 11(2): 153-9.
  22. Dashkoff N, Dashkoff PB, Zizzi JA Sr, Wadhvani J, Zizzi JA Jr. Ulnar artery cannulation for coronary angiography and percutaneous coronary intervention: case reports and anatomic considerations. *Catheterization and Cardiovascular Interventions* 2002; 55(1): 93-96.
  23. Cerda A, del Sol M. Anatomical snuffbox and its clinical significance. a literature review. *International Journal of Morphology* 2015; 33(4):1355-1360.
  24. Roghani Dehkordi F, Hashemifard O, Mansouri R, Dehghani A, Akbari M. Merits of more distal accesses in the hand for coronary angiography and intervention: trans palmar approach. *Clinical Cases in Complex Cardiovascular Therapy (International Conference)* 2017; April 19- 31, Shiraz, Iran, pp: 80-81.
  25. Kiemeneij F. Left distal transradial access in the anatomical snuffbox for coronary angiography (IdTRA) and interventions (IdTRI). *EuroIntervention* 2017; 13(7):851-857
  26. Babunashvili A, Dundua D. Recanalization and reuse of early occluded radial artery within 6 days after previous transradial diagnostic procedure. *Catheterization and Cardiovascular Interventions* 2011; 77(4):530-536.
  27. Kaledin AL, Kochanov IN, Seletskiï SS, Arkharov IV, Burak TIA, Kozlov KL. Peculiarities of arterial access in endovascular surgery in elderly patients. *Advances in Gerontology* 2014; 27(1):115-119
  28. Joshi SB, Vatsalaswamy P, Bahetee BH. Variation in formation of superficial palmar arches with clinical implications. *Journal of Clinical and Diagnostic Research* 2014; 8(4): AC06-AC09.

29. Suman U, Jayanthi KS. A Study of complete superficial palmar arches formed entirely by ulnar artery. *Journal of Anatomical Society of India* 2011; 60(2): 199-201.
30. Rao S, Vollala VR, Pamidi N, Nagabhooshana S, Kumar Potu B. Variant formation and distribution of the superficial palmar arch. *Indian Journal of Plastic Surgery* 2010; 43(1): 116-117.